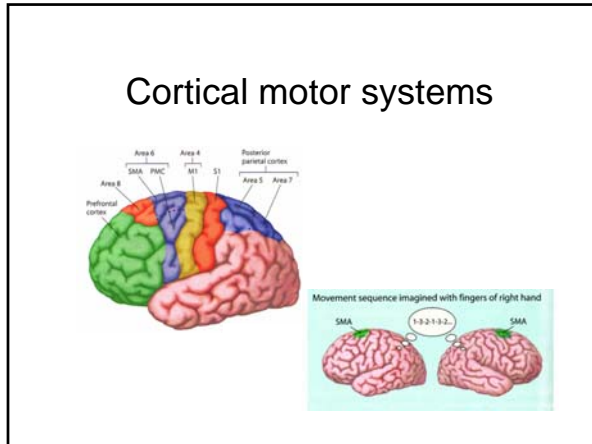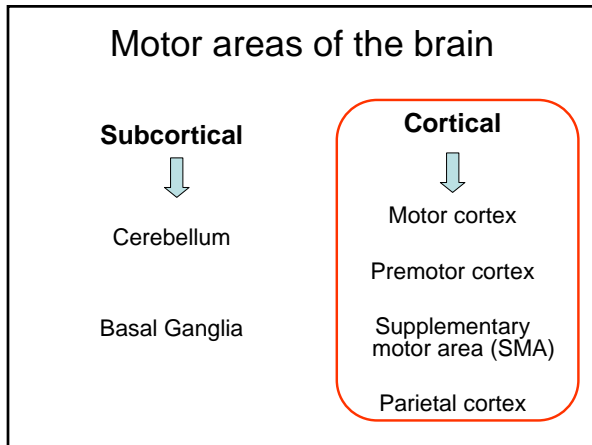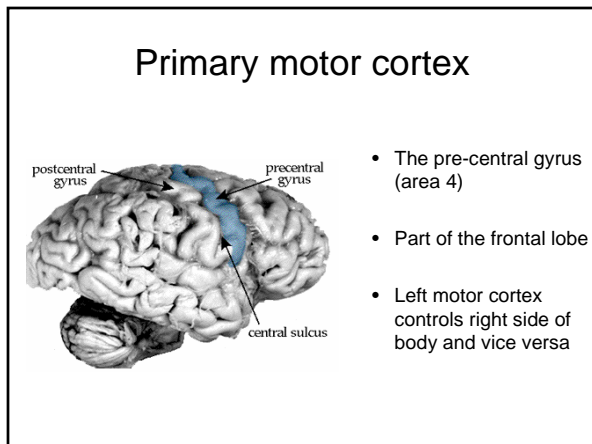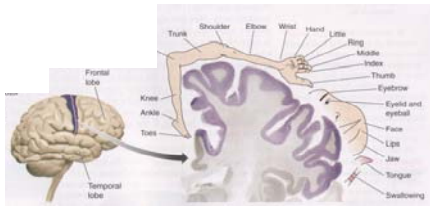


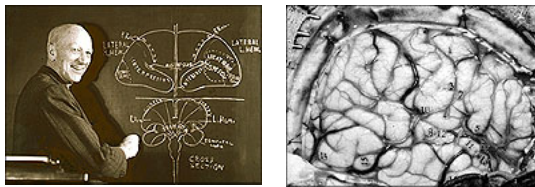
Motor cortex: Homunculus



- Somatotopic organization
 - Upside down
- Areas of **elaborate control** (i.e. hands, and lips) have larger cortical area
- Stimulating each location of the somatotopic map causes increase in tension in the corresponding muscle



Mapping the Motor Cortex

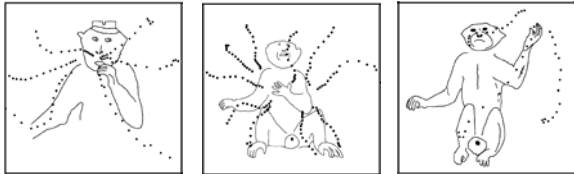


- Penfield, a Canadian surgeon
- Applied electric currents to the brain's surface, while operating on epileptic patients
- Patients awake, could tell what they were experiencing
- Movement of the patients' bodies revealed motor cortex map

Duration of stimulation

- Penfield and many other studies
 - brief trains of electrical impulses (20 ms)
 - evoke muscle twitches
- Graziano et al. (2002)
 - longer train of impulses (500 ms)
 - closer to behaviorally relevant timescale
 - evoked more complex, coordinated movements (e.g., reaching, grasping)
 - the twitch evoked by a short stimulation could be the beginning of longer movement

Longer electrical stimulation



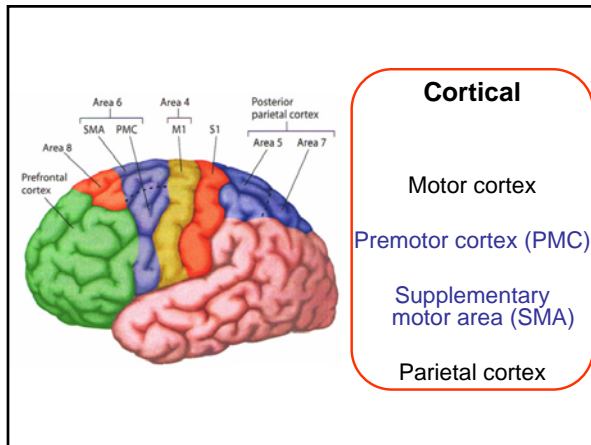
- Causes joints to move into a specific final posture, regardless of initial position
- Joints remained in final configuration until stimulation ended
- Evoked postures have behavioral significance (e.g., putting food in mouth, defending side of the head from threat)

TMS

- Transcranial Magnetic Stimulation
- Slow TMS (1 Hz)
 - produces activation
- Rapid TMS (>10 Hz)
 - results in suppression (“temporary lesion”)
- Frequency of stimulation matters

Control of Movement Revisited

- Traditional view
 - motor cortex contains a map of body’s musculature
 - activity in each location of the somatotopic map, causes the corresponding muscle to move
- More recent view
 - complex relationship between cortex and muscles
 - organized in terms of behaviorally useful actions, aimed towards a goal posture



Cortical

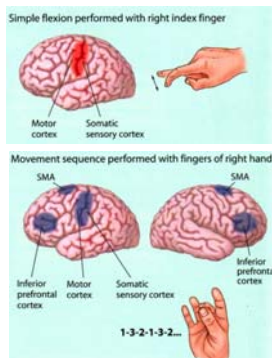
Motor cortex

Premotor cortex (PMC)

Supplementary motor area (SMA)

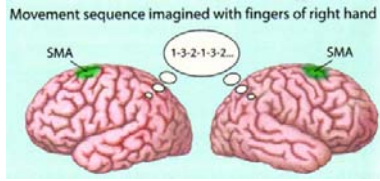
Parietal cortex

The Supplementary Motor Area (SMA)



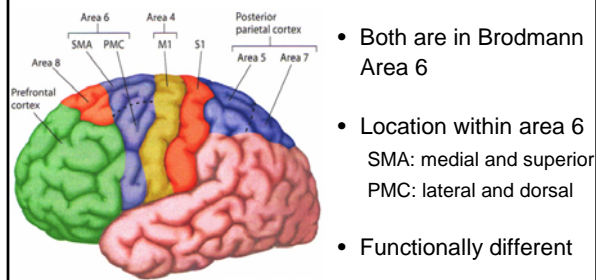
- Activated, in addition to motor cortex, during movement sequences
- Bilateral activation
- Activated during the preparatory phase of a delayed movement task

The Supplementary Motor Area (SMA)



- Activated during *imagined* movement
- No motor cortex activation
- SMA controls movement at a more abstract level

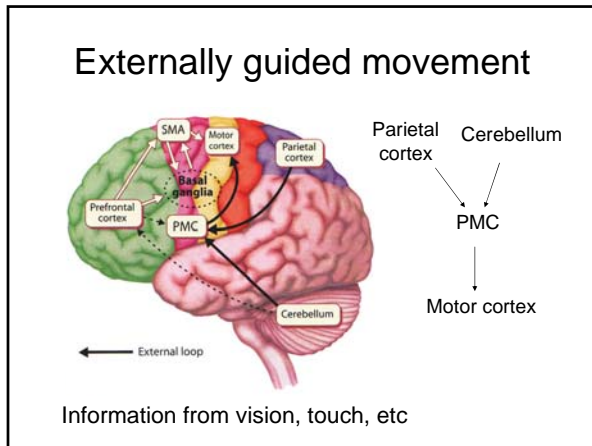
SMA vs Premotor cortex (PMC)

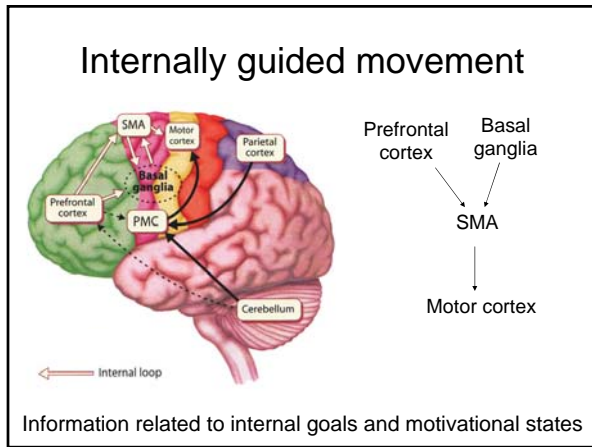


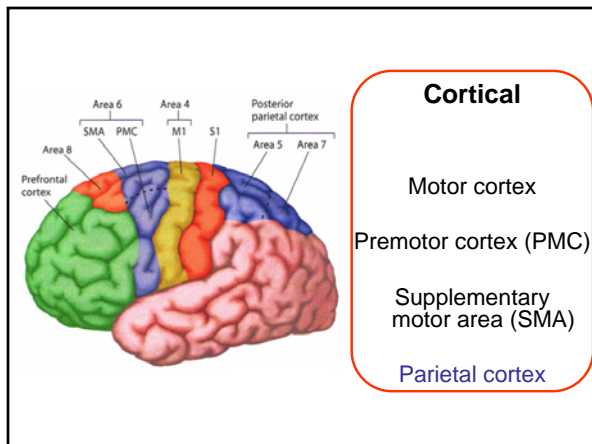
- Both are in Brodmann Area 6
- Location within area 6
SMA: medial and superior
PMC: lateral and dorsal
- Functionally different

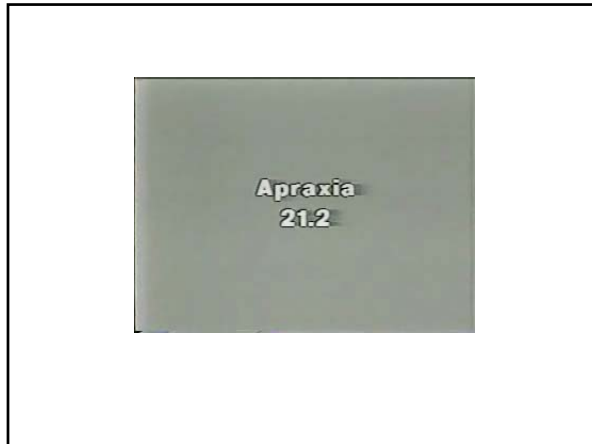Internal vs External Guidance of Movement

- Externally-guided movements
 - task depends on external clues
 - e.g., movements under the guidance of visual, auditory, or somatosensory feedback
 - supported by PMC
- Internally-guided movements
 - task performed without visual (or other sensory) guidance
 - e.g., sequential finger tapping
 - supported by SMA










Apraxia

- Literally, "no action"
- Problem in coordination of movement
- Control of muscles preserved

- Associated with left hemisphere lesions
- Most frequent when lesion includes parietal cortex


- Often accompanied by aphasia
- Assessed by asking patients to produce goal-directed gestures

Apraxia



- Patients most impaired when trying to pantomime an action
- For example: "show me how you slice a loaf of bread"
- Patient may form a fist and pound the table

Apraxia



- When given the object, the performance improves
- Some clumsiness and inappropriate movements remains
